

Stevens-Johnson Syndrome Induced by Methotrexate, An Uncommon Adverse Drug Reaction: A Case Report

Vishakha Gupta^{1,✉}, Afroz Abidi¹

¹Department of Pharmacology, Era's Lucknow Medical College, Lucknow

Abstract

Adverse drug reactions (ADRs) can lead to severe consequences and increased mortality rates. This case report focuses on a 41-year-old woman, who developed methotrexate-induced Stevens-Johnson syndrome (SJS), emphasizing the importance of recognizing and managing such a patient. The patient exhibited recurrent vomiting, maculopapular rashes, erosions and ulcers in multiple locations, consistent with SJS. These symptoms highlight the severity of the adverse drug reaction. Treatment involved was the discontinuation of medications, oral ointments, gargles, prophylactic antibiotics, and blood transfusion. Significant improvement was observed after 15 days of treatment. This case report underscores the life-threatening nature of methotrexate-induced SJS. Early recognition, discontinuation of offending medications, and prompt intervention are crucial to mitigate harm. Raising awareness about ADRs and their management is vital for enhancing patient safety and outcomes.

Keywords

Methotrexate; Stevens-Johnson syndrome; Pharmacovigilance; Adverse drug reactions; Causality Assessment

Introduction

Adverse drug reactions (ADRs) are an important contributor to a significant number of morbidity and mortality in the healthcare industry, which manifests as harmful and undesired responses to the drug at prescribed doses. According to the World Health Organization (WHO), adverse drug reactions (ADRs) are defined as "Any response to a drug that is noxious and unintended, and that occurs at doses typically used in humans for the prophylaxis, diagnosis, or therapy of disease or the modification of physiological function¹.

WHO Programme for International Drug Monitoring (PIDM) focuses on Pharmacovigilance and is vital in advancing drug safety worldwide. It aims to provide reliable and balanced information to assist public health programs in evaluating the risk-benefit profile of different medications¹. In India, NCC-PvPI-IPC (National Coordination Centre-Pharmacovigilance Programme of India- Indian Pharmacopoeia

Commission), in collaboration with WHO, is working to ensure the safety of prescribed medicines and medical products. Pharmacovigilance is done by gathering information regarding ADRs from healthcare providers, pharmaceutical companies, and consumers and making drug safety and medical product information available to healthcare professionals, regulatory authorities, pharmaceutical companies, and the general public². Standardized assessment tools, known as the causality assessment system, are used to identify ADRs and determine their relationship with a drug. The most recommended and popularly used ones are the Uppsala Monitoring Centre (WHO-UMC) assessment scale and

Corresponding Author

Dr. Vishakha Gupta
Junior Resident, Department of
Pharmacology, Era's Lucknow
Medical College, Lucknow,
Uttar Pradesh
Email
drvishakhagupta22@gmail.com

How to cite:

Gupta V., Abidi A., Volume I, Issue I, Stevens-Johnson syndrome induced by Methotrexate, an uncommon adverse drug reaction: A case report. Future Health 2023; 1(1):108-111

Submitted: 27 May 2023

Accepted: 01 September 2023

Naranjo Probability Scale³. Methotrexate is an antifolate drug that is used to treat inflammatory disorders and certain neoplastic conditions. However, methotrexate can also cause serious adverse reactions or toxicities, such as bone marrow suppression, increased risks of infections, hepatotoxicity and lung problems⁴. There are also very few studies reporting methotrexate-induced Stevens-Johnson syndrome (SJS), as it is an uncommon entity⁵. Here we are presenting Methotrexate (MTX)-induced Stevens-Johnson syndrome (SJS), a rare but life-threatening cutaneous reaction.

Case Report

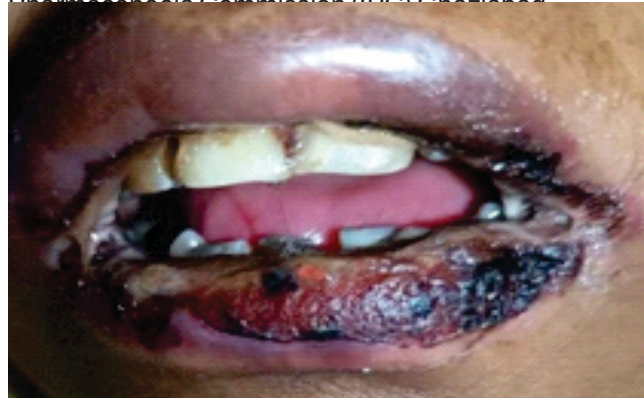A 41-Year-old female presented to the emergency department of our teaching hospital with chief complaints of recurrent vomiting for three months, maculopapular rashes, multiple erosions, and ulcers in the mouth, throat, vaginal mucosa, and buttocks for one week.

She could not take an oral diet and had become weak over time. She experienced 15-20 episodes of vomiting per day, aggravated by food intake and not getting relieved by any medication. Initially, the vomitus was watery, whitish, and not blood-tinged. But later, she had an episode of blood-mixed vomitus. She had a mild fever associated with painful ulcers in her mouth and throat, which had a sudden onset and progressed over time; however, no aggravating or relieving factors could be identified. On examination, there were multiple hemorrhagic erosion and ulcers with crusting over lips, buccal mucosa [Fig 1], and vaginal mucosa [Fig.2.]. The ulcers were discrete, oval-shaped, reddish to black, but no pus-filled lesions were observed. She also had multiple erosions over her buttocks, legs, and hand [Fig.3.].

Concerning her medical history, she has been suffering from rheumatoid arthritis for almost ten years with irregular medication and was on tablet methotrexate. She used to have severe pain in her joints while waking up. The pain was in both small and large joints of the hands and feet. There was no history of other illnesses or addictions. Her appetite was good earlier but decreased for three months, and she started having dysphagia for a solid diet. On arrival at the emergency, her general appearance was sick, and her vitals were as follows: Blood pressure-110/70 mm Hg, heart rate-90 beats per minute, respiratory rate-19/min, and body temperature-101 0F. She could not speak, eat or drink due to pain in ulcers and vomiting. Her bone marrow aspiration showed pancytopenia. Endoscopy showed

esophagitis and antral gastritis. Blood Investigations revealed Hb-6.7 gm%; TLC- 2600/cub.mm.; Platelets-50 thousand; Blood Urea-90 mg/dl; S creatinine-5.8 mg/dl, S. uric acid-11.3 mg/dl. Viral markers were non-reactive. The patient was evaluated and was diagnosed with Stevens- Johnson syndrome. All the previous medications were discontinued. She was treated with injectable steroids and antihistaminic drugs, prophylactic injectable antibiotics, oral ointments and paints, gargles/mouth wash. She also underwent a blood transfusion as her Hb and platelets were low. The lesions started to heal after 15 days of hospitalization.

We used WHO-UMC and Naranjo scale to determine the causality of this case and categorized it under probable/likely (score = 5). This adverse drug reaction was reported in the vigiflow for further analysis by National Coordination Center (NCC) under the Pharmacovigilance programme of India (PvPI), Indian Pharmacopoeia Commission (IPC) Chennai.

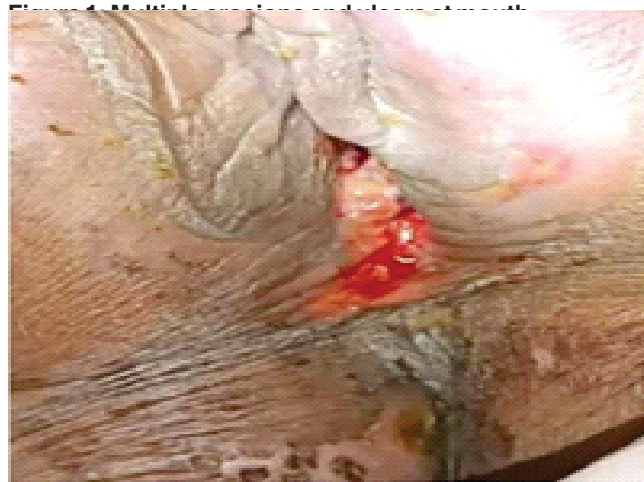

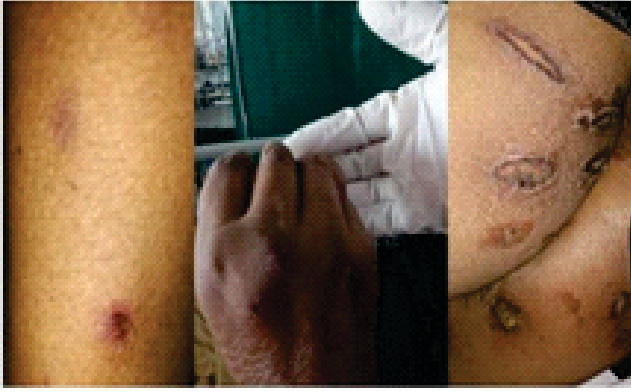


Figure 2: Erosions and ulcer at vaginal mucosa

Figure 3: Multiple erosion and ulcers at thigh, legs and buttock

Discussion

Stevens-Johnson syndrome (SJS) and toxic epidermal necrolysis (TEN) are severe cutaneous adverse drug reactions⁶. SJS/TEN is rare but is fatal. Extensive epidermal necrosis, associated with mucous membranes, and progressive severe skin detachment characterize SJS and TEN, with SJS involving less than 10% of body surface area and having a mortality rate of 1-5%. In comparison, TEN involves more than 30% skin detachment and has a mortality rate of 25-30%.

The disease initiates with influenza-like symptoms with a prodromal phase lasting 1 to 14 days. Patients may experience fever, sore throat, headache, malaise, and chills. Eventually, mucocutaneous lesions appear rapidly. Initially, rashes appear as macules and progress into papules, vesicles, bullae, or confluent erythema⁶. These lesions are primarily flat, irregular, and atypical target-shaped or widespread purpuric macules. The disease can progress to involve oral, nasal, ocular, vaginal, urethral, gastrointestinal, and lower respiratory tract mucous membranes. There is also a risk of necrosis developing in the gastrointestinal and respiratory systems in severe cases. Many patients affected by this condition also experience ocular involvement⁷.

Early identification of this adverse drug reaction is crucial. It is essential to discontinue the use of all potentially causative medications, especially those administered within one month before the onset of the reaction. The diagnosis of SJS or TEN is primarily made based on clinical assessment, but it is crucial to confirm the diagnosis through histopathological examination⁷.

Methotrexate, an analog of folic acid, inhibits dihydrofolate reductase, blocking deoxyribonucleic acid synthesis and subsequent cell death. It exhibits anti-inflammatory effects through various mechanisms, including inhibiting purine metabolism, T-cell activa-

tion, cytokine production, intercellular adhesion molecules, and IL-1 β receptor binding. Methotrexate has multiple therapeutic uses in conditions such as Crohn's disease, severe psoriasis, psoriatic arthritis, rheumatoid arthritis, and certain malignancies, including childhood acute lymphoblastic leukemia, lymphoproliferative disorders, choriocarcinoma, and various tumors. Certain drugs like (NSAIDs), phenytoin, ciprofloxacin, penicillin-type drugs, probenecid, amiodarone, and proton pump inhibitors inhibit the renal excretion of Methotrexate (MTX) and can increase the risk of MTX-related toxicity. There is a long list of contraindications or risk factors for using methotrexate as it is a potent drug that can affect many organs and systems in the body such as chronic liver disease, liver cirrhosis, chronic alcoholism, during pregnancy or lactation, blood disorders etc. In general, Methotrexate is well tolerated at therapeutic doses of rheumatoid arthritis. In case of toxicity, it typically presents with nausea, loose stools, stomatitis, punctate cutaneous eruption, central nervous system (CNS) manifestations like headache, fatigue, impaired concentration, alopecia, fever (either drug-related or due to infection), and hematologic abnormalities, particularly macrocytosis^{8,9}.

To mitigate the toxic effects of methotrexate, leucovorin, a fully reduced folate coenzyme, can be administered. Leucovorin replenishes the intracellular pool of FH4 cofactors, helping terminate the toxic effects of methotrexate⁷.

Conclusion

Stevens Johnson syndrome is a rare but fatal adverse drug reaction associated with drugs like NSAIDs, paracetamol, penicillin, cephalosporin, anti-convulsants⁹ and levofloxacin¹⁰. There are sparse reports of SJS induced by methotrexate⁵. We present this case to raise awareness and educate clinicians about the need for caution when using methotrexate. Even in patients with a previous history of SJS, it is essential to avoid using drugs known to have the potential to cause SJS.¹¹

Declaration of patient consent

The authors certify that they have obtained all appropriate patient consent forms. The patient understand that their names and initials will not be published, and due efforts will be made to conceal their identity, but anonymity cannot be guaranteed.

References

1. World Health Organization. Pharmacovigilance: Ensuring the Safe Use of Medicines. Geneva: WHO; 2004. Available from https://apps.who.int/iris/bitstream/handle/10665/186642/9789241508254_eng.pdf.

2. Pharmacovigilance Program of India-IPC Ghaziabad [Internet]. Ghaziabad: Indian Pharmacopoeia Commission; 2021 [cited 2023 June 9]. Available from: <https://ipc.gov.in/PvPI/pub.html>.
3. Zaki SA. Adverse drug reaction and causality assessment scales. *Lung India*. 2011 Apr 1; 28(2):152-3.
4. Hanoodi M, Mittal M. Methotrexate. [Updated 2023 Jan 16]. In: Stat Pearls [Internet]. Treasure Island (FL): Stat Pearls Publishing; 2023 Jan-. Available from: <https://www.ncbi.nlm.nih.gov/books/NBK556114>
5. Arora S, Abidi A, Fatima F, Hasan R, Rizvi D, Thadani A. Methotrexate induced Stevens Johnson syndrome: a rare case report. *Era's Journal of Medical Research*. 2018 Jul 1; 5(2):194-6
6. Barvaliya M, Sanmukhani J, Patel T, Paliwal N, Shah H, Tripathi C. Drug-induced Stevens-Johnson syndrome (SJS), toxic epidermal necrolysis (TEN), and SJS-TEN overlap: a multicentric retrospective study. *Journal of postgraduate medicine*. 2011 Apr 1; 57(2):115.
7. Tartarone A, Lerosé R. Stevens-Johnson syndrome and toxic epidermal necrolysis: what do we know? *Therapeutic drug monitoring*. 2010 Dec 1; 32(6):669-72
8. Roujeau JC, Kelly JP, Naldi L, Rzany B, Stern RS, Anderson T, Auquier A, Bastuji-Garin S, Correia O, Locati F, Mockenhaupt M. Medication use and the risk of Stevens-Johnson syndrome or toxic epidermal necrolysis. *New England Journal of Medicine*. 1995 Dec 14; 333(24):1600-8.
9. Brunton L L.; Knollmann B C; Goodman & Gilman's the Pharmacological Basis of Therapeutics. 14th ed. New York: McGraw-Hill Education; 2017
10. Shrivastava S., Abidi A. Levofloxacin induced Steven Johnson Syndrom. *IOSR Journal of Dental and medical Sciences (IOSR-JDMS)*. 2021;20(06) pp. 99-52.
11. Miya R, Malpani AK, Keri S, Panagaon R. Drug Induced Steven-Johnson Syndrome (SJS). *Indian Journal of*