



## Case Report

# Giant palmar lipoma with median nerve neuropathy: A case report

Rajiv Kaul<sup>1</sup> , Mohammed Schezan Iqbal<sup>2</sup>, Neha Akhoon<sup>3</sup>

<sup>1</sup>Department of Orthopaedics, Military Hospital Dehradun, <sup>2</sup>Department of Orthopaedics, INHS Asvini, Mumbai, <sup>3</sup>Department of Dermatology and Venereology, Government Medical College Jammu, India.

### \*Corresponding author:

Rajiv Kaul,  
Department of Orthopaedics,  
Military Hospital Dehradun,  
Garhi Cantonment, Dehradun,  
India.

[drrajivkaul@gmail.com](mailto:drrajivkaul@gmail.com)

Received: 18 June 2024

Accepted: 27 June 2024

Epub Ahead of Print:  
20 July 2024

Published: 16 October 2024

### DOI:

10.25259/FH\_44\_2024

### Quick Response Code



## ABSTRACT

Lipomas are familiar and routinely encountered soft-tissue tumors, which are generally asymptomatic; however, when they become too large or when they are present at some unusual locations, such as the hand, they can cause pressure symptoms due to neurological compression. We report the case of a 55-year-old lady with carpal tunnel syndrome due to a giant palmar lipoma. She was successfully treated with tumor excision and nerve decompression, thus highlighting the key points in diagnosis and precautions to be taken during surgery so that untoward complications can be avoided.

**Keywords:** giant lipoma; deep palmar space; median nerve; compressive neuropathy; nerve decompression

## INTRODUCTION

Lipomas are termed ‘giant’ when they are 5 cm or more in diameter.<sup>1</sup> They arise from mesenchymal fibrofatty tissue and generally behave as asymptomatic and gradually progressive proliferations. Although rare, a few cases of compressive neuropathy by lipomas arising from the palm have been described in the literature.<sup>2</sup> We report one such case of carpal tunnel syndrome arising from a large palmar lipoma.

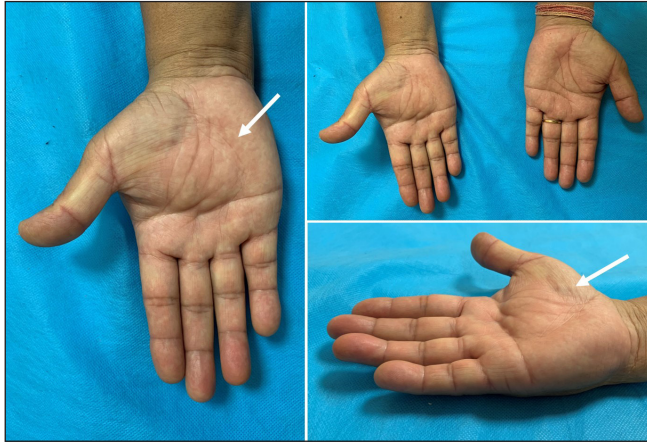
## CASE REPORT

A 55-year-old moderately built lady presented with progressive swelling over the palmar aspect of her right hand (dominant hand) over the past 12 months, along with paraesthesias and numbness in the radial three fingers, affecting her dexterity and grip strength. There was no history of trauma or heavy manual work. She had a known case of hypertension and hypercholesterolemia on pharmacotherapy (telmisartan and rosuvastatin) with no drug allergies.

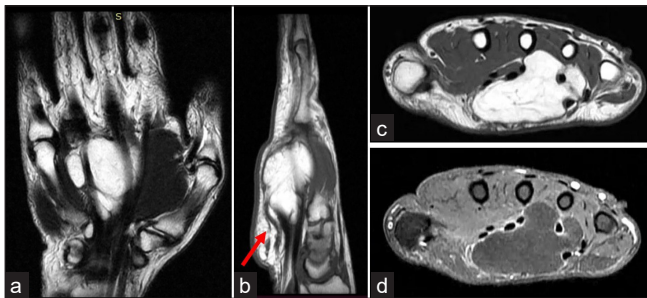
On examination, a non-tender, rubbery mass was palpable over the volar aspect of the mid-palmar region [Figure 1]. An area of hypoesthesia with altered “two-point discrimination” over the index and middle finger was noted. The classical Phalen’s and Tinel’s signs were positive at the wrist. Radiographs of the hand were normal, barring a large soft-tissue silhouette. Magnetic resonance imaging (MRI) revealed a lobulated, well-defined, hyperintense mass on T1-weighted images involving deep palmar space, measuring 45×42×26 mm [Figure 2]. The mass showed signal loss on T2-weighted fat-suppressed images, much like that of the adjacent adipose tissue. Interdigitations between the third and fourth volar interosseous compartments

This is an open-access article distributed under the terms of the Creative Commons Attribution-Non Commercial-Share Alike 4.0 License, which allows others to remix, transform, and build upon the work non-commercially, as long as the author is credited and the new creations are licensed under the identical terms.

©2024 Published by Scientific Scholar on behalf of Future Health



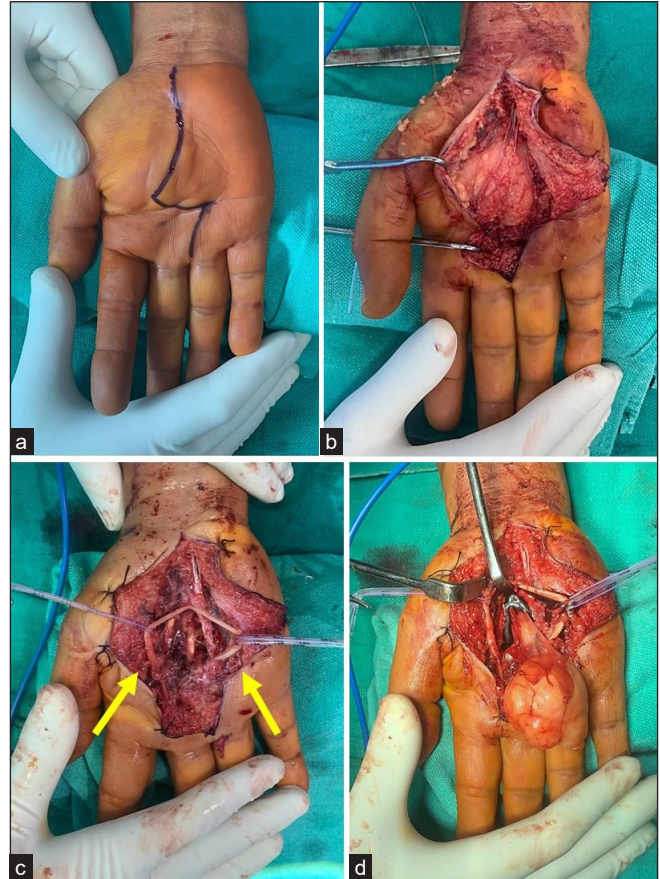
**Figure 1:** Clinical images of the palmar swelling (white arrows) over the right hand.



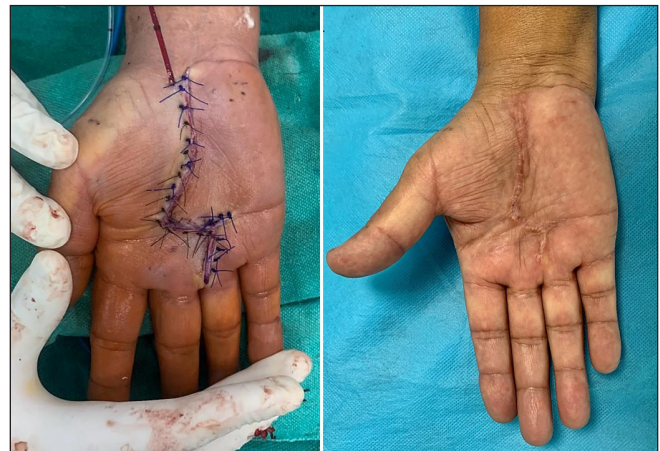**Figure 2:** Magnetic resonance imaging showing (a-c) a large, irregular but well-defined mass on the palmar aspect measuring 45 x 42 x 26 mm in size. The mass appears hypointense on T1 (b) The median nerve can be seen (red arrow) compressed by the mass (d) same section shows signal loss on T2 weighted fat suppressed images, with displacement of flexor tendons, and palmar muscles; the component bones of the wrist are normal with homogeneous structure and regular bone contour; findings suggestive of a typical encapsulated subcutaneous lipoma.

and displacement of all flexor tendons were observed. The findings were consistent with a giant-sized lipoma involving the deep palmar space. Differentials included liposarcoma, fibrolipoma, neurofibroma, and giant cell tumor of tendon sheath.<sup>3</sup> Additional investigations such as electromyography (EMG) and nerve conduction velocity (NCV) were done, which were consistent with median nerve compressive neuropathy.

Under ultrasound-guided brachial plexus block and tourniquet control, a palmar incision culminating in a Brunner-type extension was given [Figure 3]. The mass was found to be adherent to the median nerve and its branches. Meticulous dissection was performed to excise this tumor in totality. Care was taken to preserve the branches of the median nerve, notably the palmar digital nerve and the recurrent motor branch, also known as the “million-dollar nerve”<sup>4</sup> [Figure 3]. The transverse carpal ligament was divided to decompress the carpal tunnel. After achieving hemostasis, the



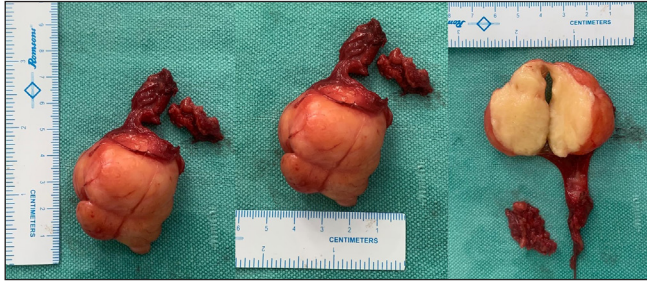**Figure 3:** (a) Volar incision used for approaching the mass; (b) Median nerve blended with capsule; (c) Excision of mass along with capsule in totality (yellow arrows); (d) Preservation of deep branches of the median nerve.



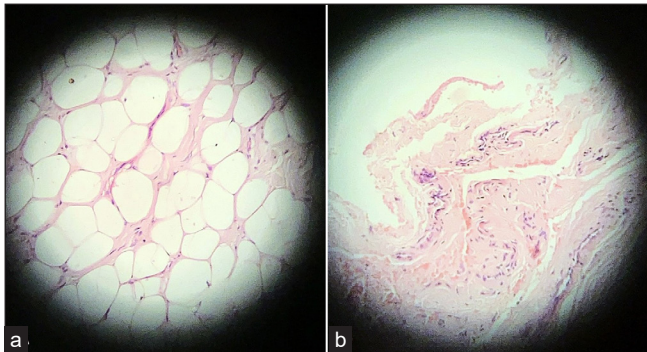
**Figure 4:** Closure and postoperative scar at 3 months.

incision was closed in a single layer over a drain [Figure 4]. Postoperatively, the wrist was splinted for 2 weeks, followed by active wrist and finger range-of-motion (ROM) and grip-strengthening exercises.





**Figure 5:** Gross cut specimen measuring 5 cm × 3.6 cm, with well-circumscribed capsule and lobulated septations.



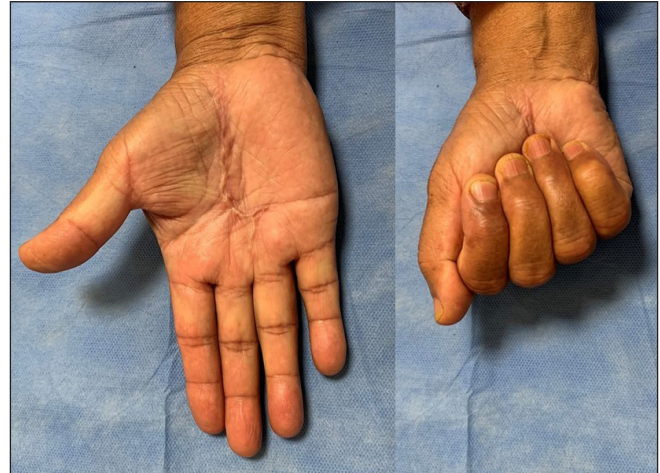**Figure 6:** (a) Histological appearance of the lipoma: uniform cells with cytoplasmic vacuoles suppressing the nucleus toward the cell membrane; (b) Cyst wall showing dense, collagenized fibrous tissue with focal myxoid areas along with muscular arteries, skeletal muscle, and fibro-fatty tissue.

The gross cut specimen measured 50 × 36 mm. It had a firm, rubbery consistency, with a well-circumscribed capsule and lobulated septations [Figure 5]. A histopathological examination (HPE) showed mature adipocytes, without atypia or necrosis, separated by broad septa of fibro-collagenous tissue [Figure 6]. Adipocytes had well-defined borders and flattened peripheral nuclei. The cyst wall showed dense collagenized fibrous tissue with focal myxoid areas along with muscular arteries, skeletal muscle, and fibro-fatty tissue and was not lined by synovium.

The patient was followed up at 3-monthly intervals up to a year. At the final follow-up, she was examined clinically, during which a complete recovery of the erstwhile sensory-motor deficits in the radial three digits was observed. A Jamar hand-held dynamometer (JLW Instruments, Chicago, Illinois, USA) was used to assess the grip strength, which was 23 kg on the affected side and 25 kg on the contralateral side. The surgical site bore a neat, cosmetic scar, and there were no signs of recurrence of the mass at the end of 12 months [Figure 7].

## DISCUSSION

Lipomas are the most frequent tumors in the human body, accounting for almost 50% of all soft-tissue neoplasms, and



**Figure 7:** Cosmetic scar with good grip strength at 12 months follow-up.

occur in up to 2% of a healthy population.<sup>5</sup> Their etiology is complex and multifactorial; traumatic, genetic, and metabolic factors such as hyperlipidemia have been implicated as potential causes.<sup>4</sup> Despite their widespread distribution, lipomas occurring in the hand are rather rare. A higher incidence has been reported in individuals aged between 50 and 60 years and can cause pressure symptoms on becoming enlarged.<sup>6,7</sup> One plausible theory is that heavy manual work results in repetitive microtrauma and can be associated with the occurrence of lipomas at this location.<sup>8</sup>

Soft-tissue lipomas are categorized by their anatomic location as either superficial (subcutaneous) or deep (subaponeurotic or intramuscular).<sup>9</sup> They rarely involve deeper areas, such as synovial membranes and muscles. Microscopically, they consist of mature fat cells, mostly derived from mesenchymal pre-adipocytes.<sup>10</sup> MRI is the diagnostic modality of choice, indicated in 'giant' lipomas, to differentiate them from low-grade liposarcomas and has a reported sensitivity of 83% for diagnosing the malignant variety.<sup>11</sup> Ultrasound is an alternative, low-cost, easily accessible modality to assess the lesion as well as its relation to the surrounding structures.

Nerve compression syndromes can occur due to a deep-seated lipoma, consequent to the limited space in the hand.<sup>12</sup> Giant lipomas of the hand (>5 cm diameter) are a known cause of carpal tunnel syndrome.<sup>13</sup> Tumors of this size may often masquerade as thenar or hypothenar hypertrophy and certainly warrant a workup for malignancy. Another infrequent but hazardous complication is that of tendon erosion which can lead to spontaneous rupture of the flexor tendons of the digits.

For giant lipomas, surgery is the mainstay of treatment, providing very good long-term cosmetic and functional

results. The fundamental principles of treatment would be a safe, en-bloc excision with careful dissection of the neurovascular bundle to prevent complications and minimize the risk of recurrence. As many as 5% of cases experience local recurrence due to inadequate surgical excision.<sup>14</sup>

## CONCLUSION

The present report concurs that giant lipomas are potentially baleful afflictions of the hand. They commonly masquerade as benign swellings and are often overlooked, resulting in complications. Surgical excision is the curative remedy, and chances of recurrence are rare.

## Ethical approval

Institutional Review Board approval is not required.

## Declaration of patient consent

The authors certify that they have obtained all appropriate patient consent.

## Financial support and sponsorship

Nil.

## Conflicts of interest

There are no conflicts of interest.

## Use of artificial intelligence (AI)-assisted technology for manuscript preparation

The authors confirm that there was no use of artificial intelligence (AI)-assisted technology for assisting in the writing or editing of the manuscript and no images were manipulated using AI.

## REFERENCES

1. Yildiran G, Akdag O, Karamese M, Selimoglu M, Tosun Z. Giant lipomas of the hand. *Hand Microsurg.* 2015;4(1):8–11.3.
2. Sbai MA, Benzarti S, Msek H, Boussen M, Khorbi A. Carpal tunnel syndrome caused by lipoma: A case report. *Pan Afr Med J* 2015;22:51
3. Fletcher CDM, Bridge JA, Hogendoorn PCW, Mertens, F. WHO classification of tumours of soft tissue and bone. In *Pathology and genetics of tumours of soft tissue and bone*, 4th ed.; IARC Press: Lyon, France; 2013.
4. dos Santos Silva J, de Barros LF, de Freitas Souza R, Mendonça SM, Costa FM, Landeiro JA, *et al.* “Million-dollar nerve” magnetic resonance neurography: First normal and pathological findings. *European Radiology* 2022;32:1154–62.
5. Clesham K, Galbraith JG, Ramasamy A, Karkuri A. Giant lipoma of the hand causing median nerve compression. *Case Reports* 2017;2017:bcr-2017.
6. Ramirez-Montano L, Lopez RP, Ortiz NS. Giant lipoma of the third finger of the hand. *Springerplus* 2013;2:164.
7. Unal M, Demirayak E, Acar B, Kose O. Simultaneous median and ulnar compression neuropathy secondary to a giant palmar lipoma: A case report and review of the literature. *Cureus* 2018;10:e2198.
8. Aust MC, Spies M, Kall S, Jokuszies A, Gohritz A, Vogt P. Posttraumatic lipoma: Fact or fiction? *SKIN Med* 2007;6: 266–70
9. Singh V, Kumar V, Singh AK. Case report: A rare presentation of Giant palmar lipoma. *Int J Surg Case Rep* 2016;26:21–3.
10. Phalen GS, Kendrick JI, Rodriguez JM. Lipomas of the upper extremity: A series of fifteen tumors in the hand and wrist and six tumors causing nerve compression. *Am J Surg* 1971;121:298–306.
11. Gaskin CM, Helms CA. Lipomas, lipoma variants, and well differentiated liposarcomas (atypical lipomas): Results of MRI evaluations of 126 consecutive fatty masses. *AJR Am J Roentgenol* 2004;182:733–9.
12. De Smet L, Bande S, Fabry G: Giant lipoma of the deep palmar space, mimicking persistent carpal tunnel syndrome. *Acta Orthop Belg* 1994;60:334–5.
13. Ribeiro G, Salgueiro M, Andrade M, Fernandes VS. Giant palmar lipoma-an unusual cause of carpal tunnel syndrome. *Rev Bras Ortop* 2017;52:612–5.
14. Yavari M, Afshar A, Shahrokh Shahraki S, Tabrizi A, Doorandish N. Management of symptomatic lipoma of the hand: A case series and literature. *Arch Bone Jt Surg* 2022;10:530–5.

**How to cite this article:** Kaul R, Iqbal MS, Akhoun N. Giant palmar lipoma with median nerve neuropathy: A case report. *Future Health.* 2024;2:162-5. doi: 10.25259/FH\_44\_2024